

VASCULAR STUDIES UNIT

Level 1
Glenfield Hospital
Tel: 0116 258 5440

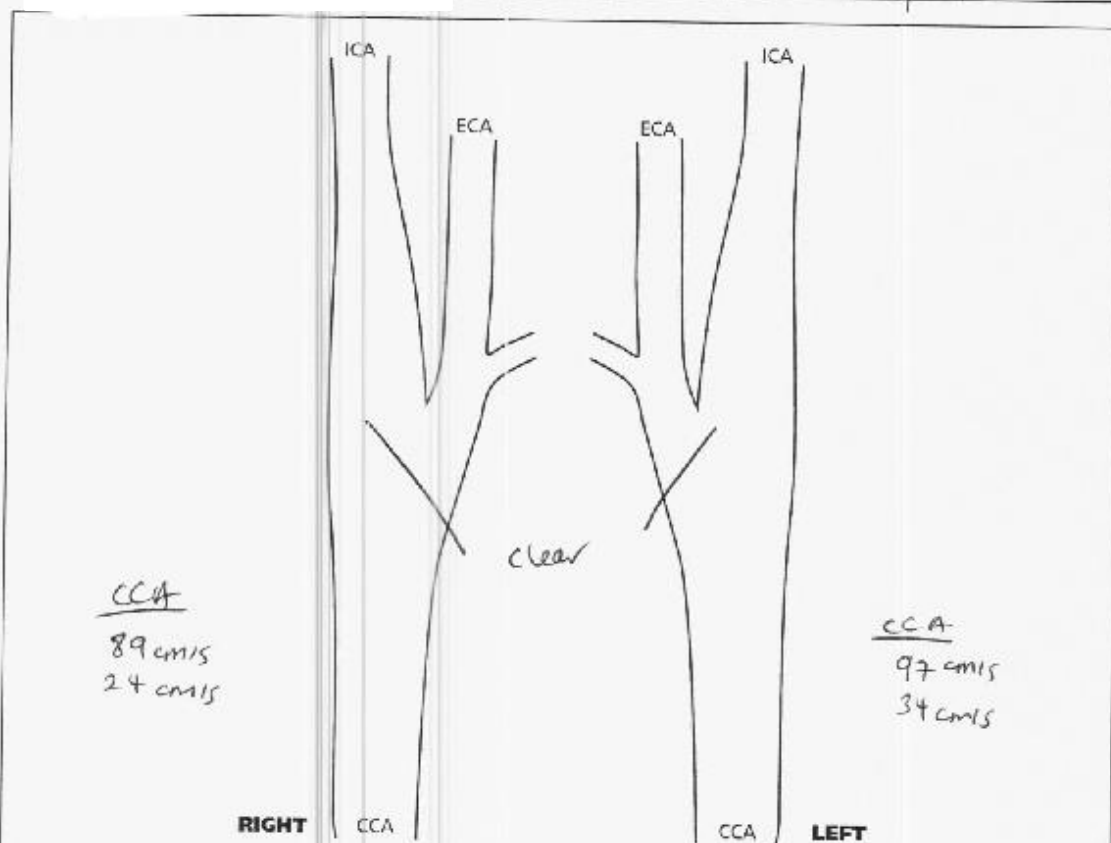


University Hospitals
of Leicester
NHS Trust

CAROTID DUPLEX SCAN REPORT

CONSULTANT: DR FOTHERBY DEPT: TIA Clinic
CLINICAL HISTORY: R eye visual disturbance HOSPITAL: CRJ

SUMMARY	%STENOSIS	ICA PSV cm/s	ICA EDV cm/s	VERTEBRAL FLOW
RIGHT	<u>0</u>	<u>71</u>	<u>25</u>	<u>Full</u>
LEFT	<u>0</u>	<u>56</u>	<u>29</u>	<u>Full</u>



COMMENTS:

SIGNED: [Signature]

CLINICAL VASCULAR SCIENTIST

PRINT NAME: S. Fotherby

DATE: 14/2/22

IMAGE QUALITY:

GOOD ☐ ☒ POOR

WCH01711442F

VASCULAR STUDIES UNIT

Level 1
Glenfield Hospital
Tel: 0116 258 5440

NHS

University Hospitals
of Leicester
NHS Trust

CAROTID DUPLEX SCAN REPORT

CONSULTANT: Dr FOTHERBY
CLINICAL HISTORY: @ eye visual disturbance

DEPT: TIA Clinic
HOSPITAL: LRI

SUMMARY	%STENOSIS	ICA PSV cm/s	ICA EDV cm/s	VERTEBRAL FLOW
RIGHT	≤ 10	62	11	FWD
LEFT	≤ 10	61	14	FWD

ICA
 $\leq 10\%$
mixed plaque
?ulcerative

CCA
64 cm/s
13 cm/s

RIGHT

CCA

ICA
 $\leq 10\%$
mixed plaque

ICA
7.1 cm/s
15 cm/s

CCA

LEFT

COMMENTS:

SIGNED: S. Fotherby

CLINICAL VASCULAR SCIENTIST

PRINT NAME: S. Fotherby

DATE: 14/2/22

IMAGE QUALITY:

GOOD ☒ POOR

IMR/ST/11/4/19

VASCULAR STUDIES UNIT

Level 1
Glenfield Hospital
Tel: 0116 258 5440

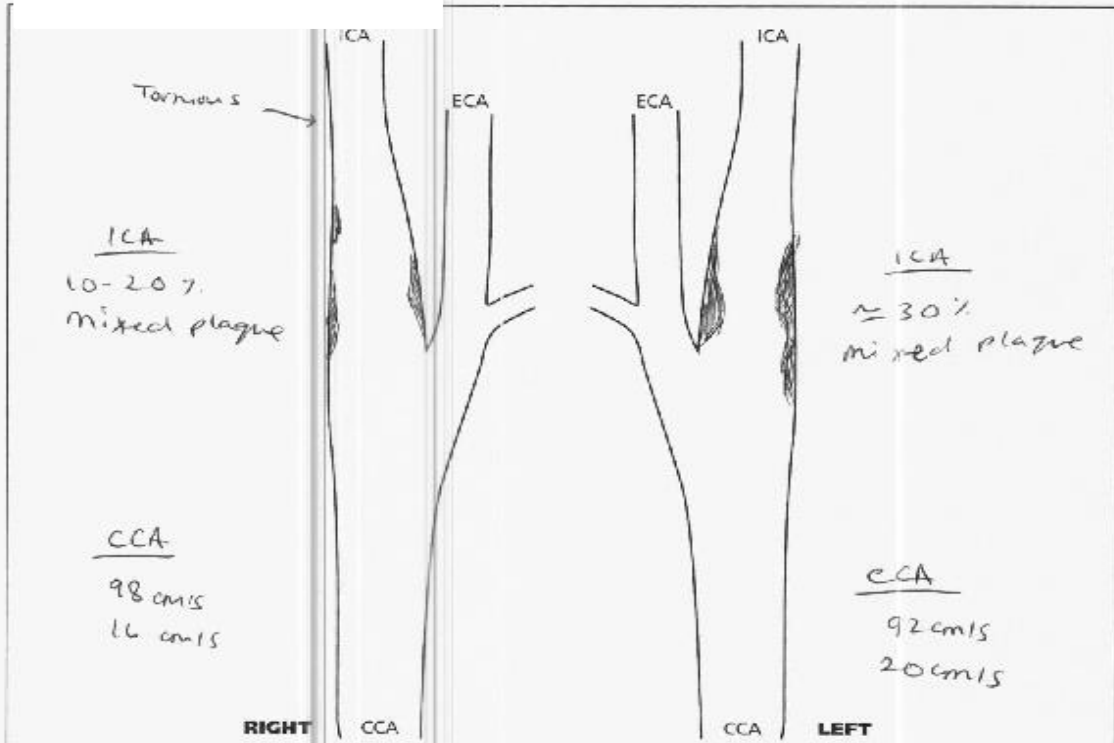


University Hospitals
of Leicester
NHS Trust

CAROTID DUPLEX SCAN REPORT

CONSULTANT: DR FOTHERBY DEPT: TIA Clinic
CLINICAL HISTORY: ② hand numbness HOSPITAL: LR1
④ eye blurred vision and slurred speech

SUMMARY	% STENOSIS	ICA PSV cm/s	ICA EDV cm/s	VERTEBRAL FLOW
RIGHT	10-20	71	21	FWD
LEFT	~30	119	36	FWD



COMMENTS:

SIGNED: *[Signature]*

CLINICAL VASCULAR SCIENTIST

PRINT NAME: S. Fotherby

DATE: 22/2/22

IMAGE QUALITY:

GOOD ☒ ☐ ☐ POOR

04/01/2011 14:03

VASCULAR STUDIES UNIT

Level 1
Glenfield Hospital
Tel: 0116 258 5440



University Hospitals
of Leicester
NHS Trust

CAROTID DUPLEX SCAN REPORT

CONSULTANT: *Dr Robinson*

DEPT: *TIA clinic*

CLINICAL HISTORY:

Confusion

HOSPITAL: *LR1*

SUMMARY	% STENOSIS	ICA PSV cm/s	ICA EDV cm/s	VERTEBRAL FLOW
RIGHT	<i>10-20</i>	<i>66</i>	<i>21</i>	<i>FWP</i>
LEFT	<i>< 20</i>	<i>70</i>	<i>20</i>	<i>FWP</i>

ICA
10-20% mixed plaque

CCA
*108 cm/s
25 cm/s*

RIGHT

CCA

ICA
< 20% mixed plaque

CCA
*112 cm/s
22 cm/s*

CCA

LEFT

COMMENTS:

SIGNED:

[Signature]

CLINICAL VASCULAR SCIENTIST

PRINT NAME:

S. Feron

DATE:

10/3/12

IMAGE QUALITY:

GOOD ☐ ☒ ☐ POOR

VASCULAR STUDIES UNIT

Level 1
Glenfield Hospital
Tel: 0115 258 5440

NHS

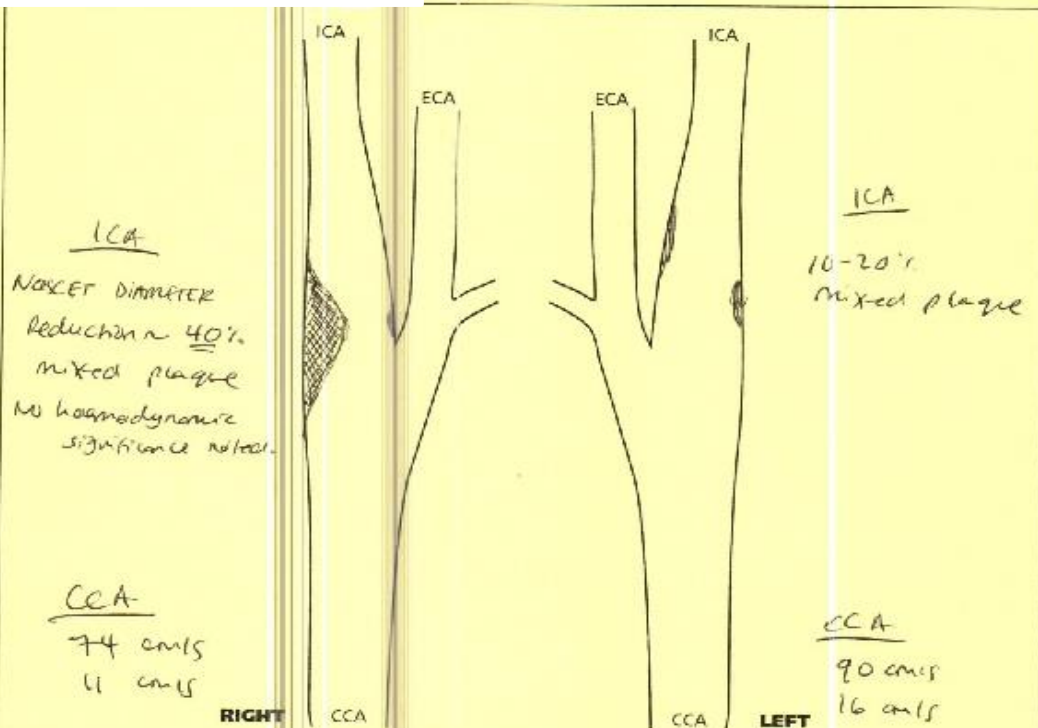
University Hospitals
of Leicester
NHS Trust

CAROTID DUPLEX SCAN REPORT

CONSULTANT: Prof Robson
CLINICAL HISTORY: Loss of vision
for approx 5 minutes.

DEPT: TIA Clinic
HOSPITAL: LR

SUMMARY	%STENOSIS	ICA PSV cm/s	ICA EDV cm/s	VERTEBRAL FLOW
RIGHT	<u>~40%</u>	<u>62</u>	<u>18</u>	<u>FWD</u>
LEFT	<u>10-20</u>	<u>43</u>	<u>14</u>	<u>FWD</u>



COMMENTS:

SIGNED: [Signature]

CLINICAL VASCULAR SCIENTIST

PRINT NAME: S. Faruqi

DATE: 10/03/22

IMAGE QUALITY:

GOOD ☐ ☒ ☐ POOR

WMA-15771-0009

VASCULAR STUDIES UNIT

Level 1
Glenfield Hospital
Tel: 0116 258 5440

NHS

University Hospitals
of Leicester
NHS Trust

CAROTID DUPLEX SCAN REPORT

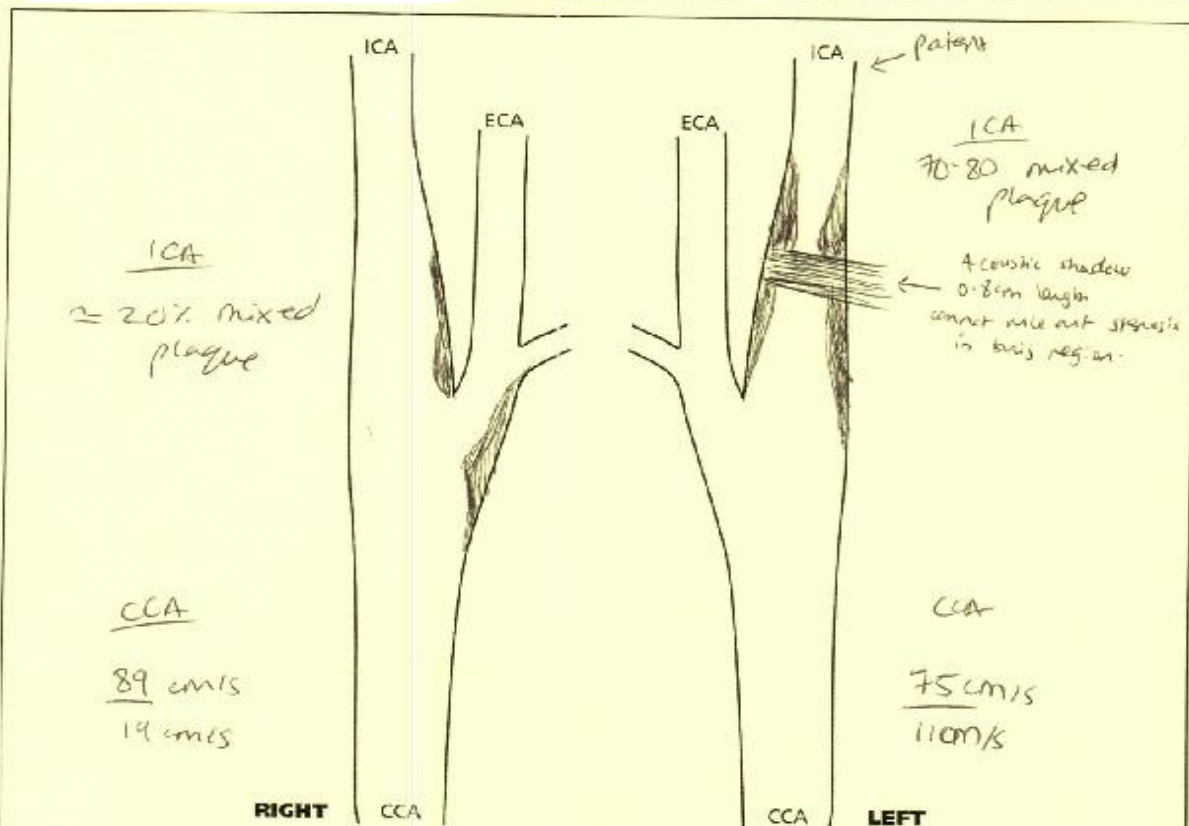
CONSULTANT: Dr Mansarant

DEPT: TIA Clinic

CLINICAL HISTORY: Double vision
for 30 mins, was not able to get up.

HOSPITAL: LRI

SUMMARY	%STENOSIS	ICA PSV cm/s	ICA EDV cm/s	VERTEBRAL FLOW
RIGHT	≈ 20	79	17	Flow
LEFT	70-80	360	260	Flow



COMMENTS:

SIGNED:

[Signature]

CLINICAL VASCULAR SCIENTIST

PRINT NAME:

S. Farver

DATE:

1/2/21

IMAGE QUALITY:

GOOD

☒

☐

☐

POOR

02600/517114400

VASCULAR STUDIES UNIT

Level 1
Glenfield Hospital
Tel: 0116 258 5440

NHS

University Hospitals
of Leicester
NHS Trust

CAROTID DUPLEX SCAN REPORT

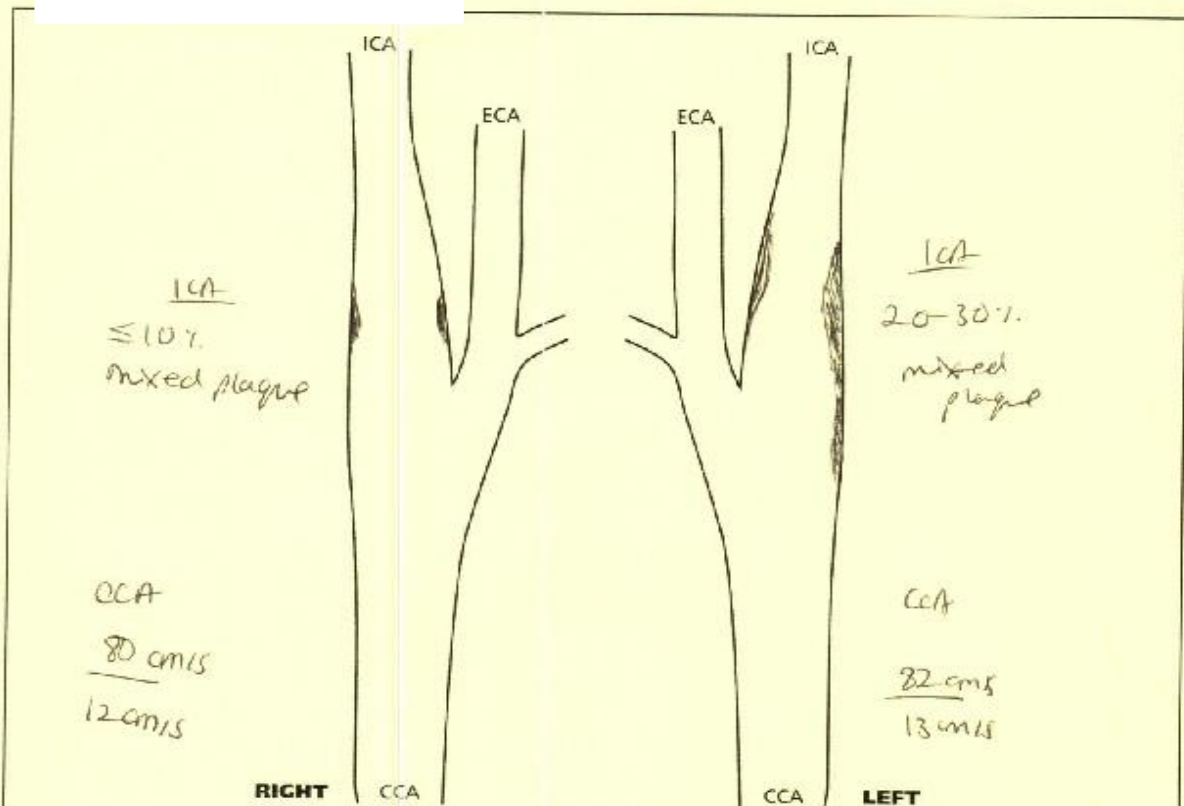
CONSULTANT: Dr Muscarel

DEPT: TIA Clinic

CLINICAL HISTORY: ① facial drop
Shrunk spleen.

HOSPITAL: LR1

SUMMARY	%STENOSIS	ICA PSV cm/s	ICA EDV cm/s	VERTEBRAL FLOW
RIGHT	≤10	63	11	Rev
LEFT	20-30	80	16	Rev



COMMENTS:

SIGNED: [Signature] CLINICAL VASCULAR SCIENTIST

PRINT NAME: S. Farnor DATE: 1/12/21

IMAGE QUALITY:

GOOD ☐ ☒ POOR

WMA/US 711-1402

VASCULAR STUDIES UNIT

Level 1
Glenfield Hospital
Tel: 0116 258 5440



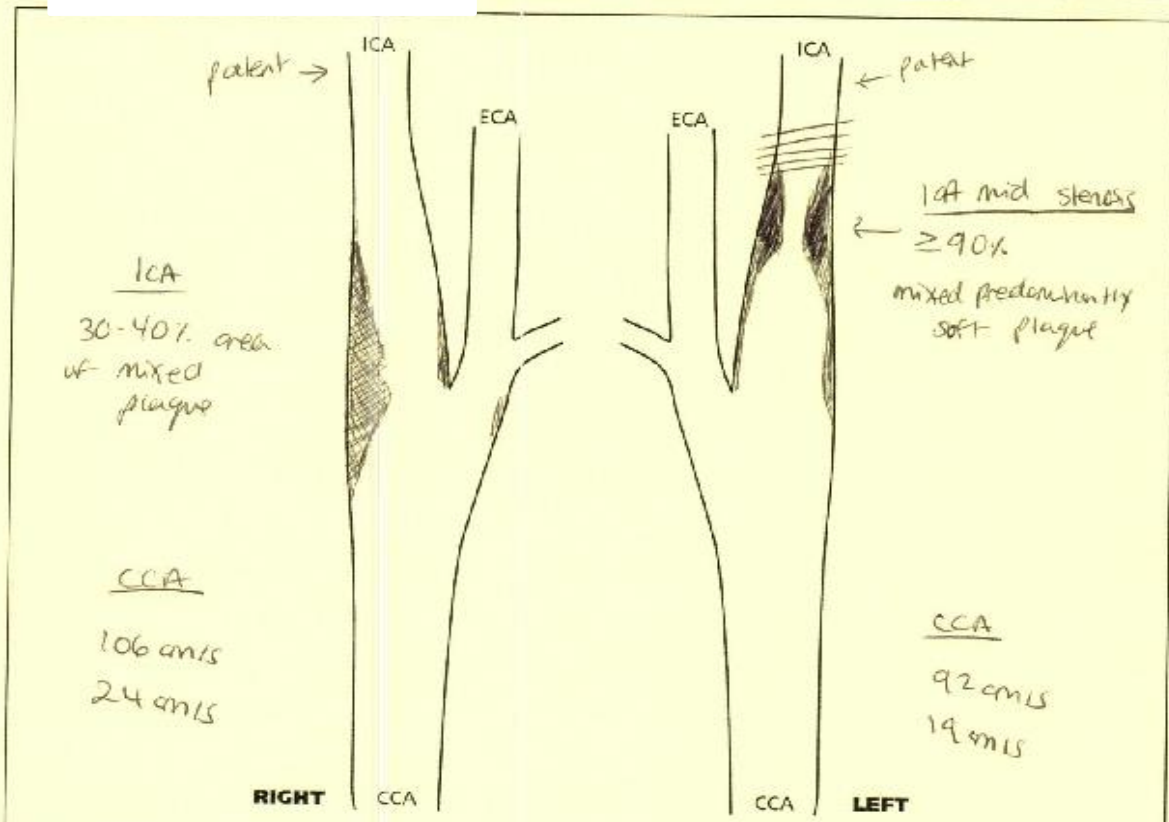
University Hospitals
of Leicester
NHS Trust

CAROTID DUPLEX SCAN REPORT

S
F
D
U

CONSULTANT: DR TREADWELL DEPT: WD 26
CLINICAL HISTORY: @ ICA stenosis on CT HOSPITAL: (TIA) LH

SUMMARY	%STENOSIS	ICA PSV cm/s	ICA EDV cm/s	VERTEBRAL FLOW
RIGHT	30-40	133	39	not seen
LEFT	≥90%	534	190	fwd



COMMENTS:

SIGNED: [Signature] CLINICAL VASCULAR SCIENTIST

PRINT NAME: S. Farah

DATE: 1/12/21

IMAGE QUALITY:

GOOD ☒ POOR ☐

WARR017111449

STROKE / TIA DETAILS

Date Index Event: _____

Date most recent symptoms: _____

Type of symptoms: Amaurosis Fugax

TIA

Stroke

Pre-op Rankin score: _____

TCD (30 minute monitoring MCA)

Side: Left / Right

Depth(cm): _____

Mean flow (cm/s): _____

Emboli: Yes ☐ No ☐

Number: _____

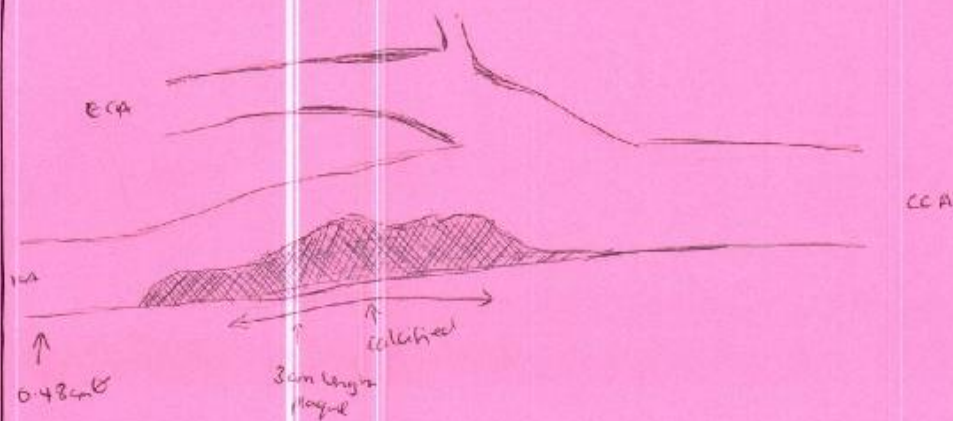TCD Window: Easy ☐ ☐ ☐ ☐ ☐ Difficult

Signature: _____

Print Name: _____

Date: _____

VSU PRE-OP CAROTID SCAN DIAGRAM



CEA side	% ICA Stenosis	ICA PSV	ICA EDV	CCA PSV	CCA EDV	ICA dist lumen dia	Bifurcation level
Left	55-60	18.4	39	87	14	0.48	Low (med) / high

Signature: *S. Fawcett*

Name: S. Fawcett

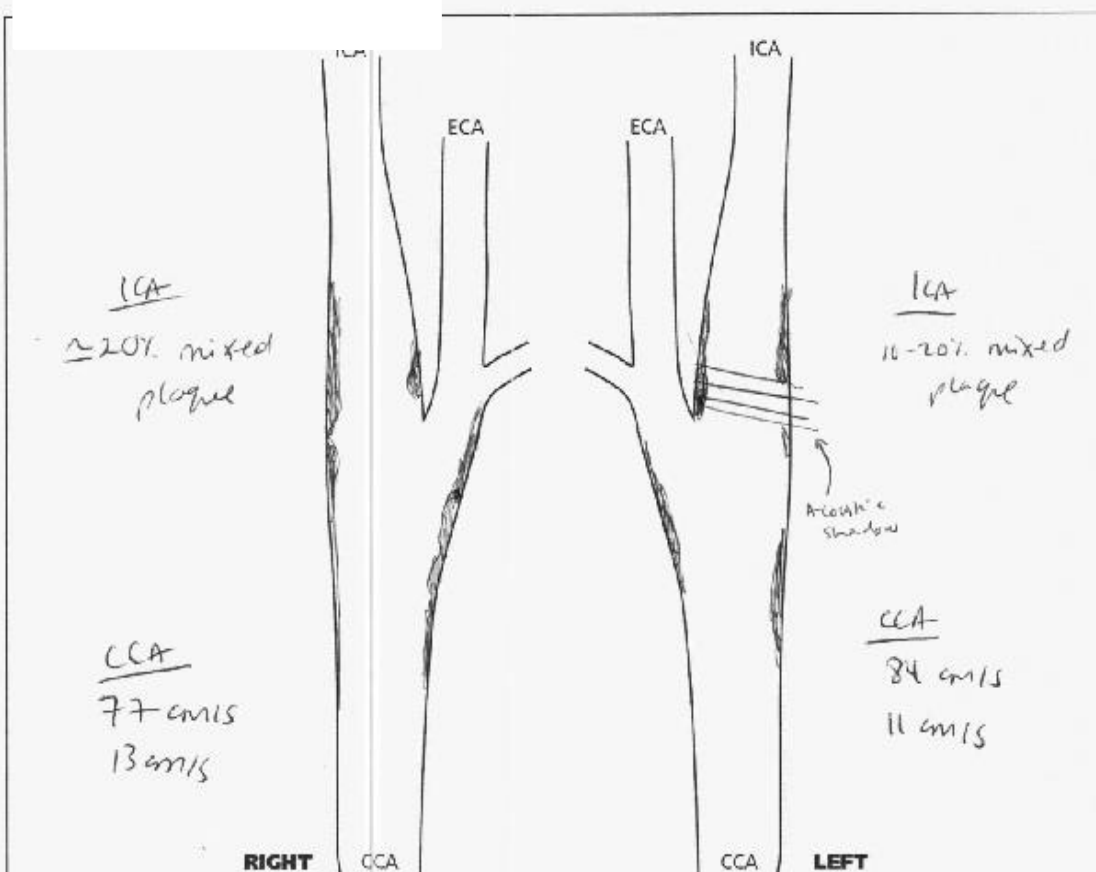
CVS date: 13/12/12

Level 1
Glenfield Hospital
Tel: 0116 258 5440

**University Hospitals
of Leicester**
NHS Trust

CONSULTANT: DR MOQSITH DEPT: W25
CLINICAL HISTORY: 7 cervical smears HOSPITAL: CR1

SUMMARY	%STENOSIS	ICA PSV cm/s	ICA EDV cm/s	VERTEBRAL FLOW
RIGHT	<u>20</u>	79	11	RWD
LEFT	10-20	75	13	FWD



COMMENTS:

SIGNED:

Quind

CLINICAL VASCULAR SCIENTIST

PRINT NAME: _____

S. ferus

DATE: 5/1/22

IMAGE QUALITY:

GOOD ☐ ☒ ☐ POOR

VASCULAR STUDIES UNIT

Level 1
Glenfield Hospital
Tel: 0116 258 5440

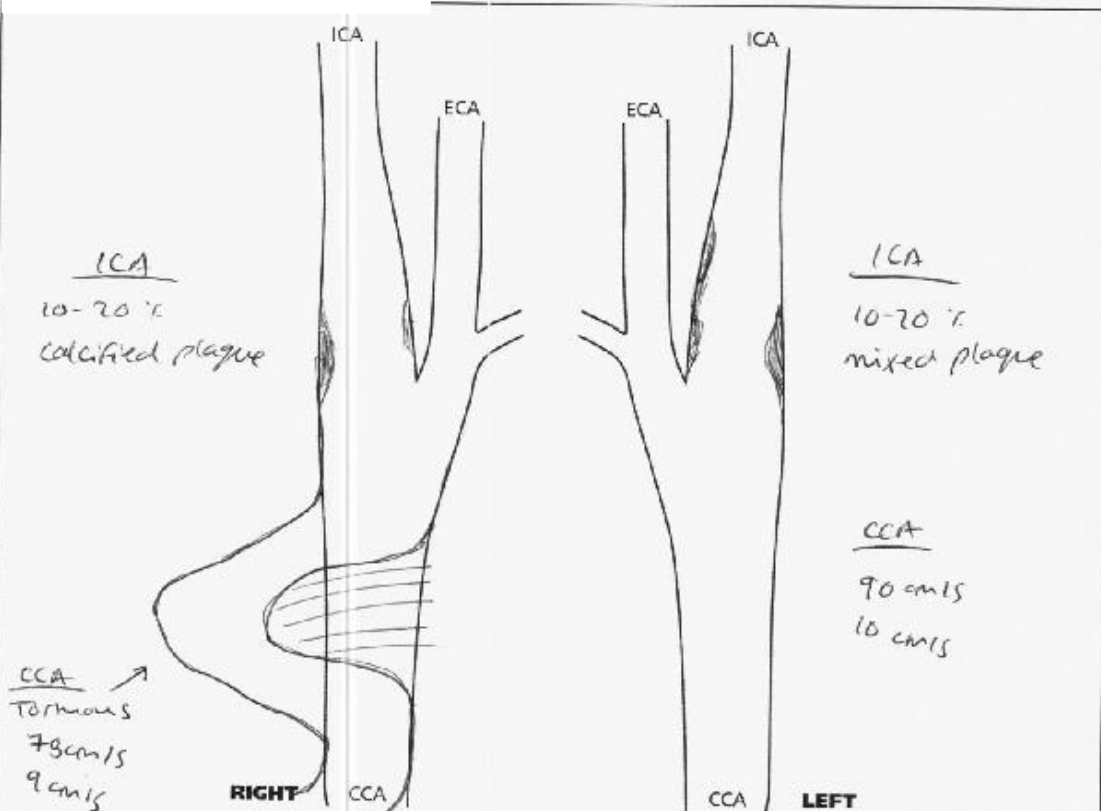


University Hospitals
of Leicester
NHS Trust

CAROTID DUPLEX SCAN REPORT

CONSULTANT: DR MANNING DEPT: TIA Clinic
CLINICAL HISTORY: (L) sided arm and leg weakness HOSPITAL: CLH

SUMMARY	%STENOSIS	ICA PSV cm/s	ICA EDV cm/s	VERTEBRAL FLOW
RIGHT	10-20	47	10	AWD
LEFT	10-20	61	13	AWD



COMMENTS: Scan conducted on chair due to pt limited mobility.

SIGNED: [Signature] CLINICAL VASCULAR SCIENTIST

PRINT NAME: S. Forth DATE: 10/1/22

IMAGE QUALITY:

GOOD ☐ ☐ ☒ POOR

VASCULAR STUDIES UNIT

Level 1
Glenfield Hospital
Tel: 0116 258 5440

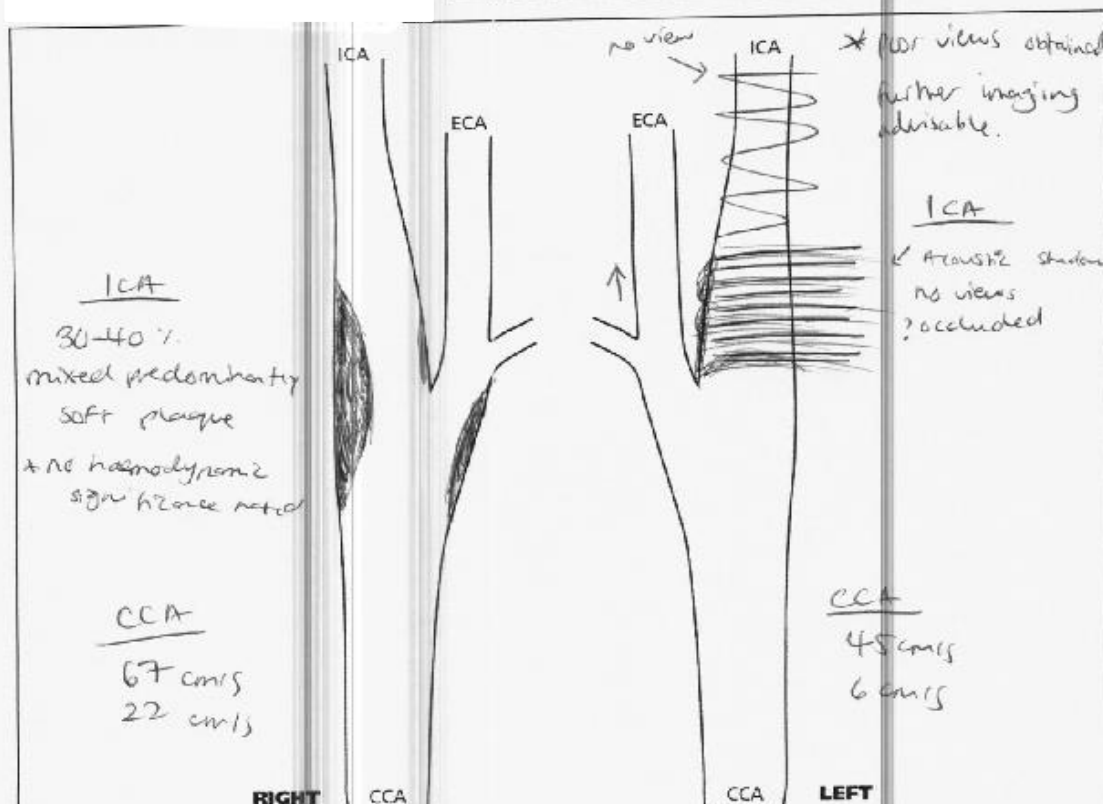
NHS

University Hospitals
of Leicester
NHS Trust

CAROTID DUPLEX SCAN REPORT

CONSULTANT: Dr Mainwaring DEPT: TIA Unit
CLINICAL HISTORY: (L) visual disturbance HOSPITAL: LRI

SUMMARY	% STENOSIS	ICA PSV cm/s	ICA EDV cm/s	VERTEBRAL FLOW
RIGHT	30-40%	61	25	Flow
LEFT	not	seen		Flow



COMMENTS: Scan performed while patient was on chair, due to poor limited mobility.

SIGNED: *[Signature]*

CLINICAL VASCULAR SCIENTIST

PRINT NAME: S. Farman

DATE: 25/1/22

IMAGE QUALITY:

GOOD ☐ ☐ ☒ POOR

Waters 0171164468

VASCULAR STUDIES UNIT

Level 1
Glenfield Hospital
Tel: 0116 258 5440



University Hospitals
of Leicester
NHS Trust

CAROTID DUPLEX SCAN REPORT

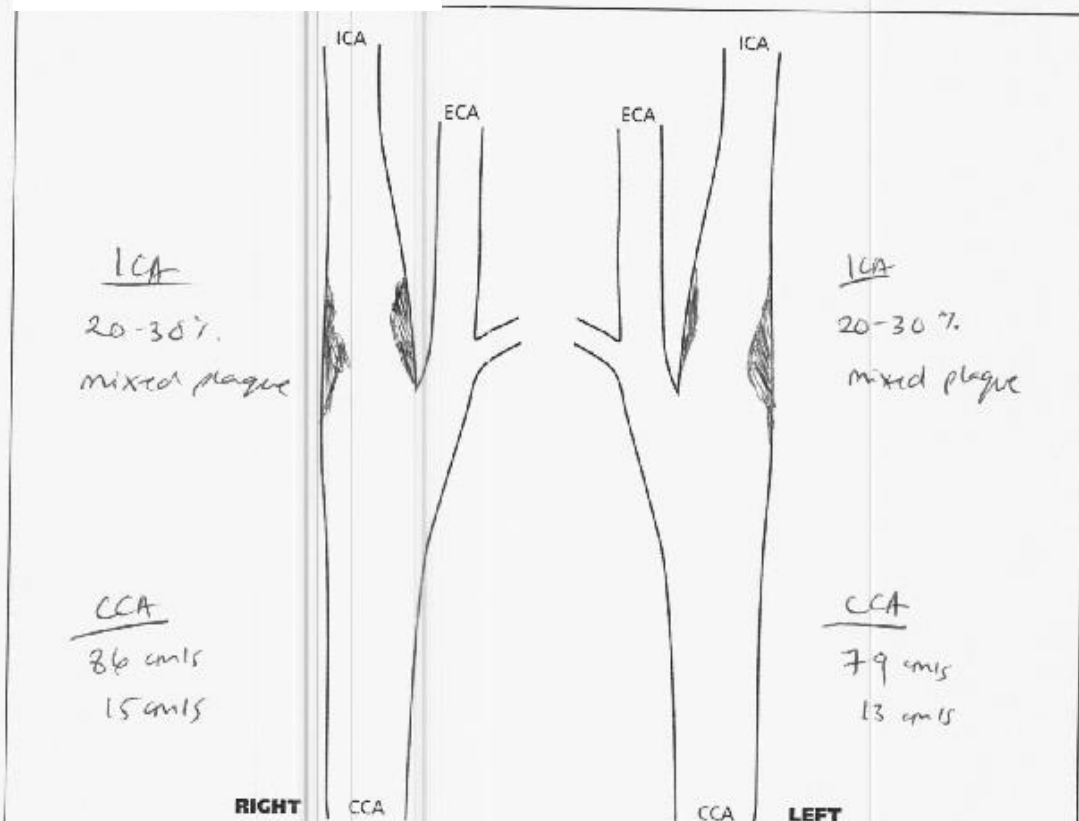
CONSULTANT: *Prof Robinson*

DEPT: *TIA Clinic*

CLINICAL HISTORY: *felt unsteady on feet*

HOSPITAL: *UPL*

SUMMARY	%STENOSIS	ICA PSV cm/s	ICA EDV cm/s	VERTEBRAL FLOW
RIGHT	<i>20-30</i>	<i>49</i>	<i>12</i>	<i>FW</i>
LEFT	<i>20-30</i>	<i>58</i>	<i>15</i>	<i>FW</i>



COMMENTS:

SIGNED: *[Signature]*

CLINICAL VASCULAR SCIENTIST

PRINT NAME: *S. Foster*

DATE: *10/2/22*

IMAGE QUALITY:

GOOD ☐ ☒ POOR ☐

VASCULAR STUDIES UNIT

Level 1
Glenfield Hospital
Tel: 0115 258 5440

NHS

University Hospitals
of Leicester
NHS Trust

CAROTID DUPLEX SCAN REPORT

CONSULTANT: Mr Davies

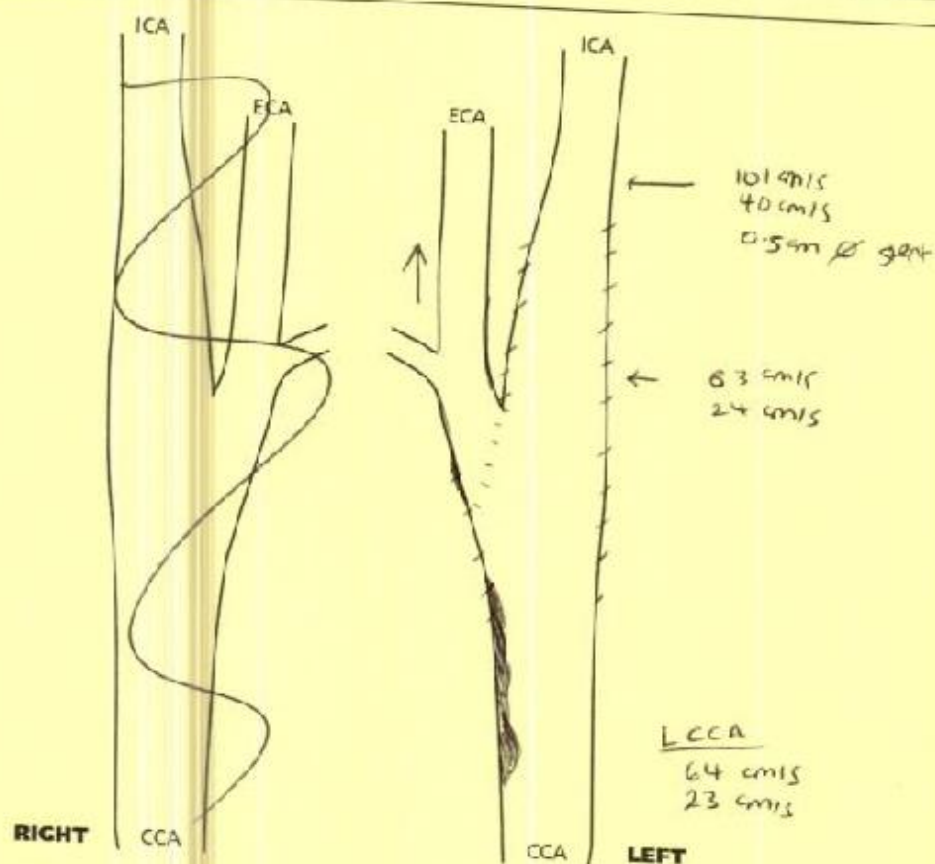
DEPT: VSU

CLINICAL HISTORY:

HOSPITAL: GH

CONT'D. spent surveillance

SUMMARY	%STENOSIS	ICA PSV cm/s	ICA EDV cm/s	VERTEBRAL FLOW
RIGHT				
LEFT	0	63	24	FWD



COMMENTS: Patient reports no problems, remains on atorvastatin.
Scan remains the same as previously reported
FU booked in 12 months - 3/2/23 @ 2.30pm

SIGNED: *[Signature]*

CLINICAL VASCULAR SCIENTIST

PRINT NAME: S. Fash

DATE: 11/2/22

IMAGE QUALITY:

GOOD ☐ ☒ POOR

1000005171114401

VASCULAR STUDIES UNIT

Level 1
Glenfield Hospital
Tel: 0116 258 5440



University Hospitals
of Leicester
NHS Trust

CAROTID DUPLEX SCAN REPORT

CONSULTANT: Mr McMahon

DEPT: USU

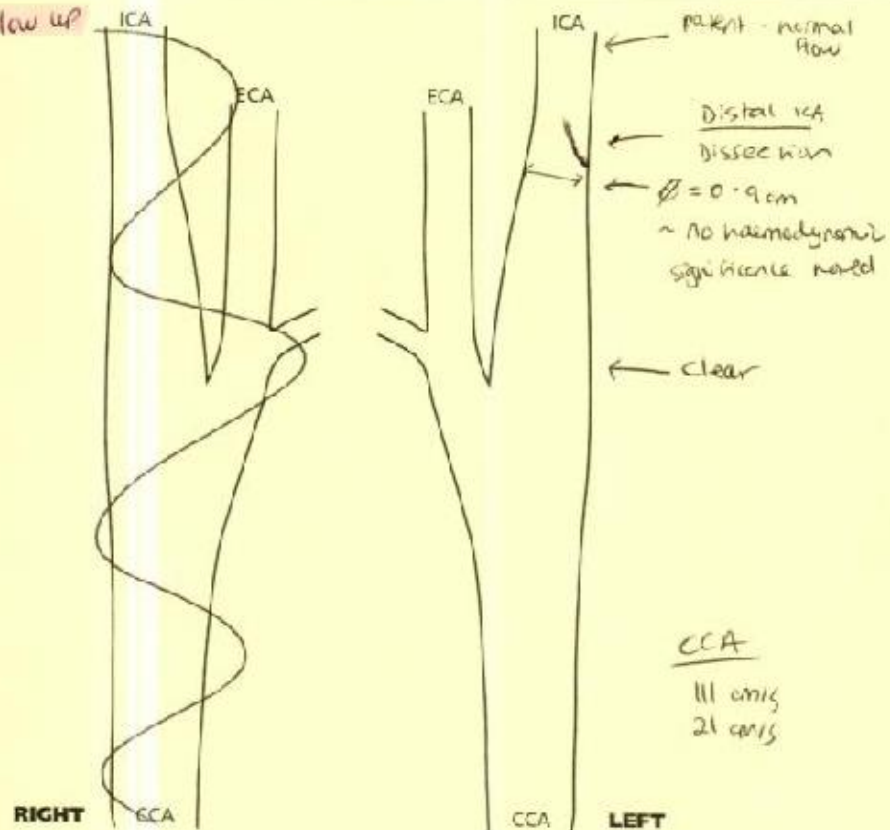
CLINICAL HISTORY:

① carotid dissection
12 month fu

HOSPITAL: GH

SUMMARY	%STENOSIS	ICA PSV cm/s	ICA EDV cm/s	VERTEBRAL FLOW
RIGHT				
LEFT	0	75	29	FWO

* No further follow up
booked.



COMMENTS: patient reports no problems. No changes noted on scan.
No further follow up booked

SIGNED: Rainab

CLINICAL VASCULAR SCIENTIST

PRINT NAME: S. Shah

DATE: 11/2/22

IMAGE QUALITY:

GOOD ☐ ☒ POOR

VASCULAR STUDIES UNIT

Level 1
Glenfield Hospital
Tel: 0116 258 5440



University Hospitals
of Leicester
NHS Trust

CAROTID DUPLEX SCAN REPORT

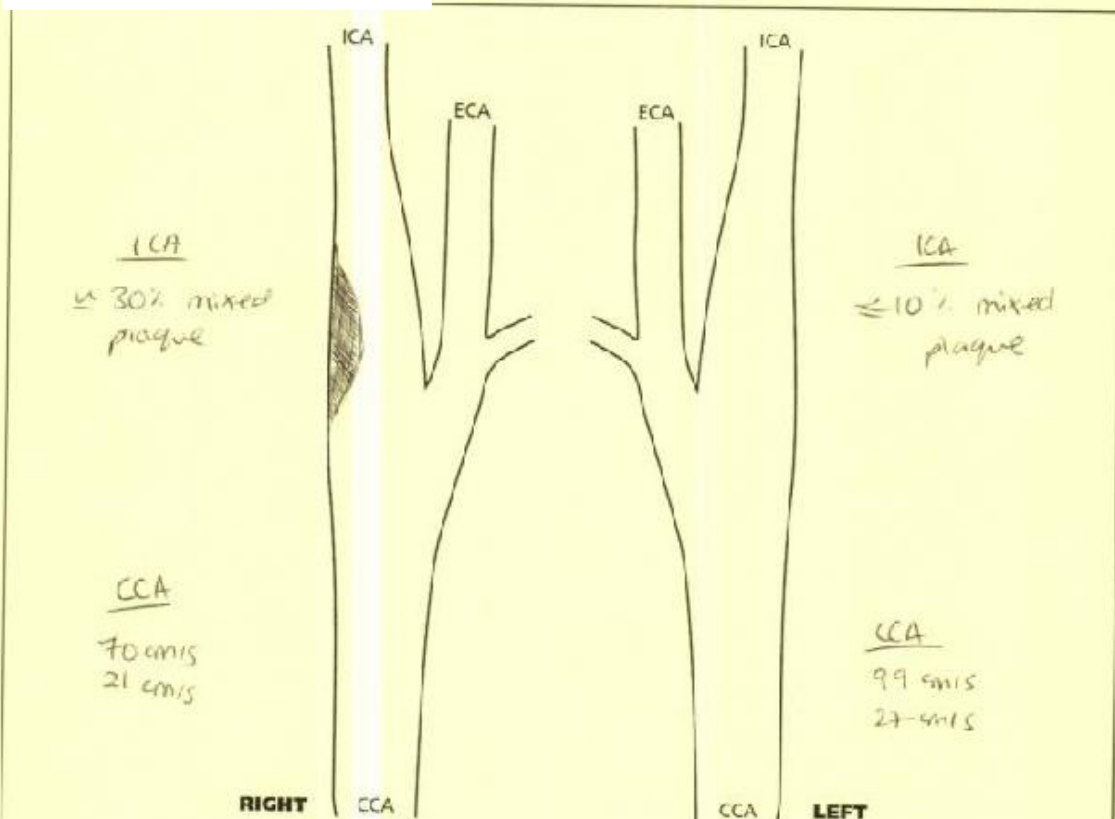
CONSULTANT: GSM

DEPT: VSU

CLINICAL HISTORY: E carotid bruit

HOSPITAL: CH

SUMMARY	%STENOSIS	ICA PSV cm/s	ICA EDV cm/s	VERTEBRAL FLOW
RIGHT	~30	83	33	FWD
LEFT	≤10	79	27	FWD



COMMENTS:

SIGNED: *S. Farah*

CLINICAL VASCULAR SCIENTIST

PRINT NAME: S. Farah

DATE: 18/2/22

IMAGE QUALITY:

GOOD ☐ ☒ POOR

18/02/22 11:40 AM

VASCULAR STUDIES UNIT

Level 1
Glenfield Hospital
Tel: 0116 258 5440

NHS

University Hospitals
of Leicester
NHS Trust

CAROTID DUPLEX SCAN REPORT

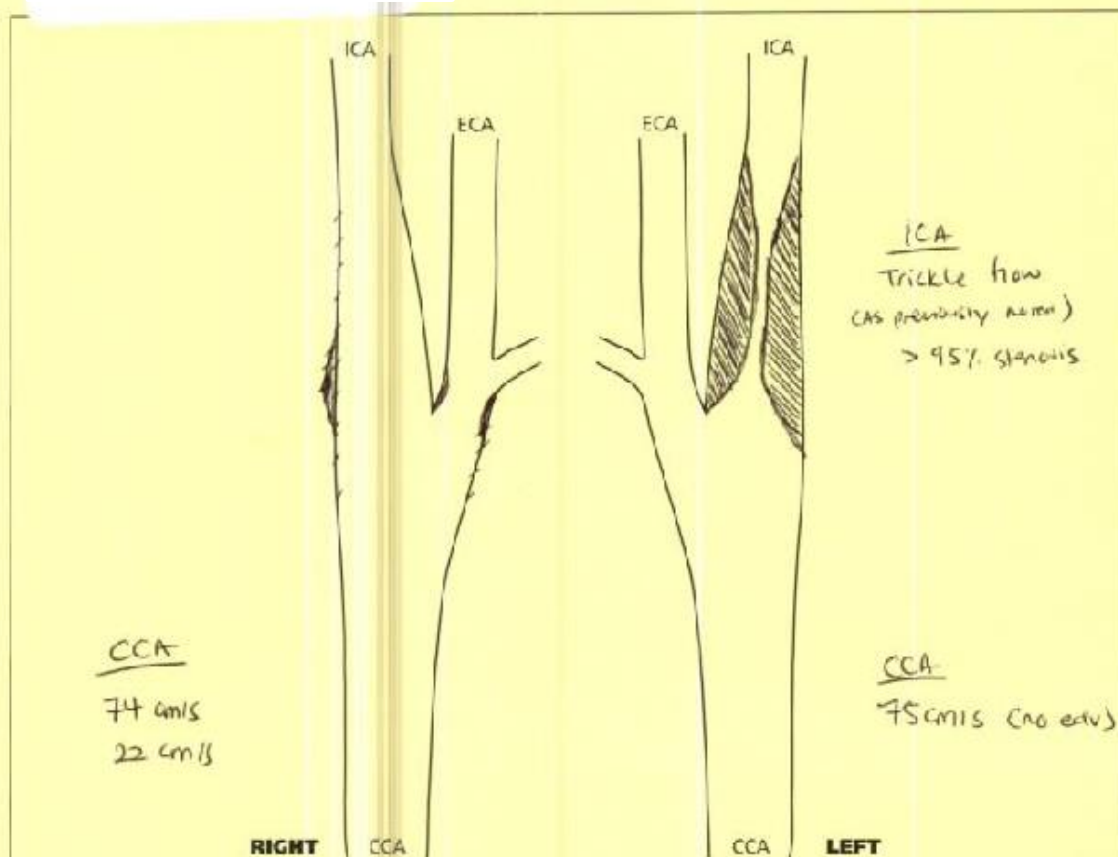
CONSULTANT: MJM

DEPT: VSV

CLINICAL HISTORY: Carotid surveillance

HOSPITAL: GH

SUMMARY	%STENOSIS	ICA PSV cm/s	ICA EDV cm/s	VERTEBRAL FLOW
RIGHT	<u>0</u>	<u>99</u>	<u>32</u>	<u>FWD</u>
LEFT	<u>>95</u>	<u>7</u>	<u>0</u>	<u>FWD</u>



COMMENTS: patient is asymptomatic reports no new symptoms. Has suffered from aphasia since his stroke many years ago.
* No changes in medication.
* f/u for 12/12 - 17/03/23 (as per patient choice).

SIGNED: [Signature]

CLINICAL VASCULAR SCIENTIST

PRINT NAME: S. Fearn

DATE: 18/03/22

IMAGE QUALITY:

GOOD ☒ POOR

VASCULAR STUDIES UNIT

Level 1
Glenfield Hospital
Tel: 0115 258 5440

NHS

University Hospitals
of Leicester
NHS Trust

CAROTID DUPLEX SCAN REPORT

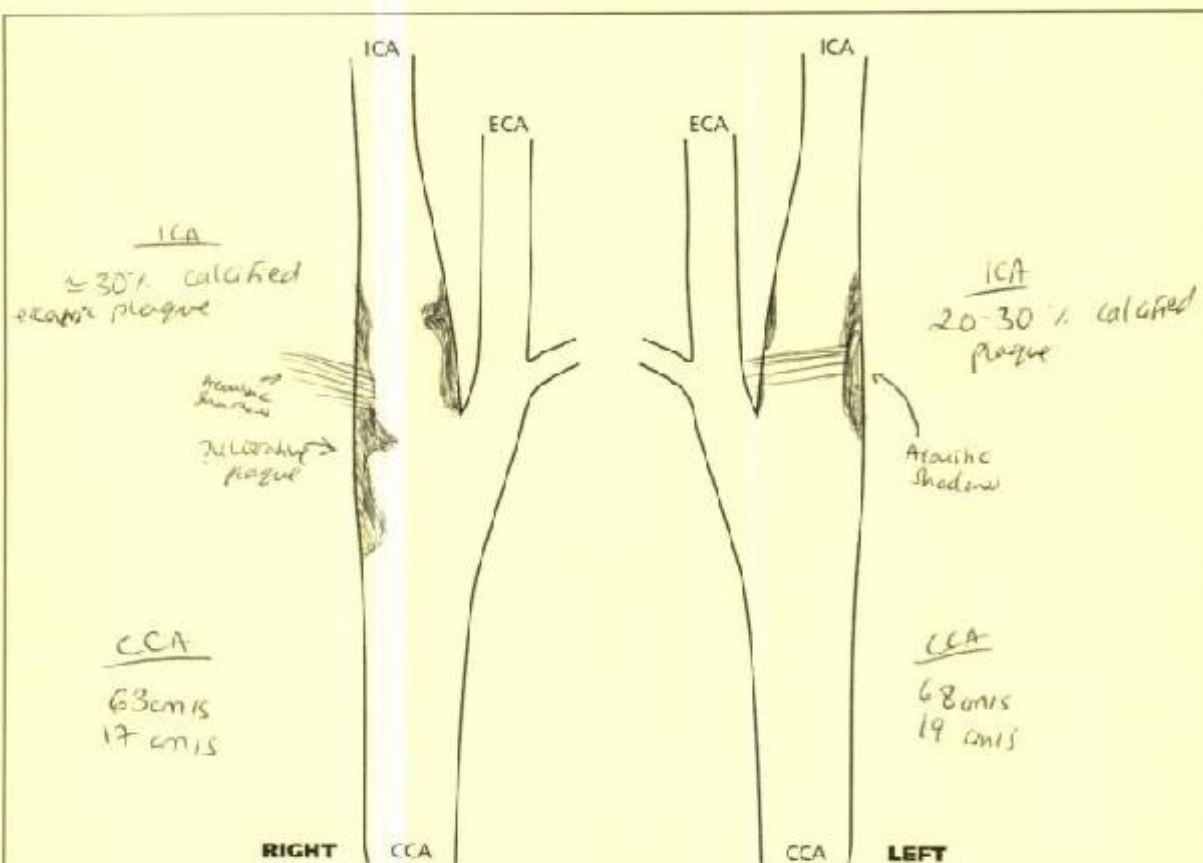
CONSULTANT: Mr Kapoor

DEPT: VSU

CLINICAL HISTORY: 2/2020 ischaemia
pt has renal cancer with spot infarct

HOSPITAL: CH

SUMMARY	%STENOSIS	ICA PSV cm/s	ICA EDV cm/s	VERTEBRAL FLOW
RIGHT	~30	96	18	0
LEFT	20-30	84	35	0



COMMENTS:

SIGNED:

S. Farah

CLINICAL VASCULAR SCIENTIST

PRINT NAME:

S. Farah

DATE: 18/3/22

IMAGE QUALITY:

GOOD

☒

POOR

☐

WMA/05/17/11-4001

VASCULAR STUDIES UNIT

Level 1
Glenfield Hospital
Tel: 0116 258 5440

NHS

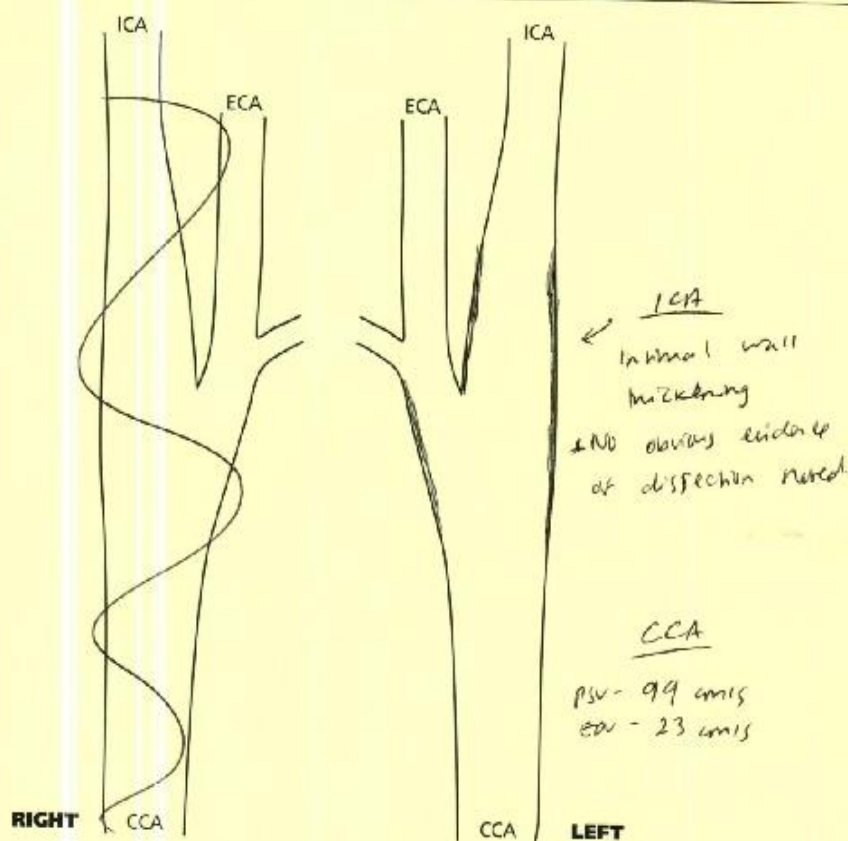
University Hospitals
of Leicester
NHS Trust

CAROTID DUPLEX SCAN REPORT

CONSULTANT: MR RAYT DEPT: VALS

CLINICAL HISTORY: 2 (L) carotid dissection HOSPITAL:

SUMMARY	%STENOSIS	ICA PSV cm/s	ICA EDV cm/s	VERTEBRAL FLOW
RIGHT				
LEFT	<u>0</u>	<u>49</u>	<u>21</u>	<u>RWD</u>



COMMENTS: NO obvious evidence of (L) carotid dissection was observed.

SIGNED: [Signature] CLINICAL VASCULAR SCIENTIST

PRINT NAME: S. Farn DATE: 5/4/22

IMAGE QUALITY

GOOD ☐ ☒ POOR

05/06/2015 17:11:44 KPS

VASCULAR STUDIES UNIT

Level 1
Glenfield Hospital
Tel: 0116 258 5440

NHS

University Hospitals
of Leicester
NHS Trust

CAROTID DUPLEX SCAN REPORT

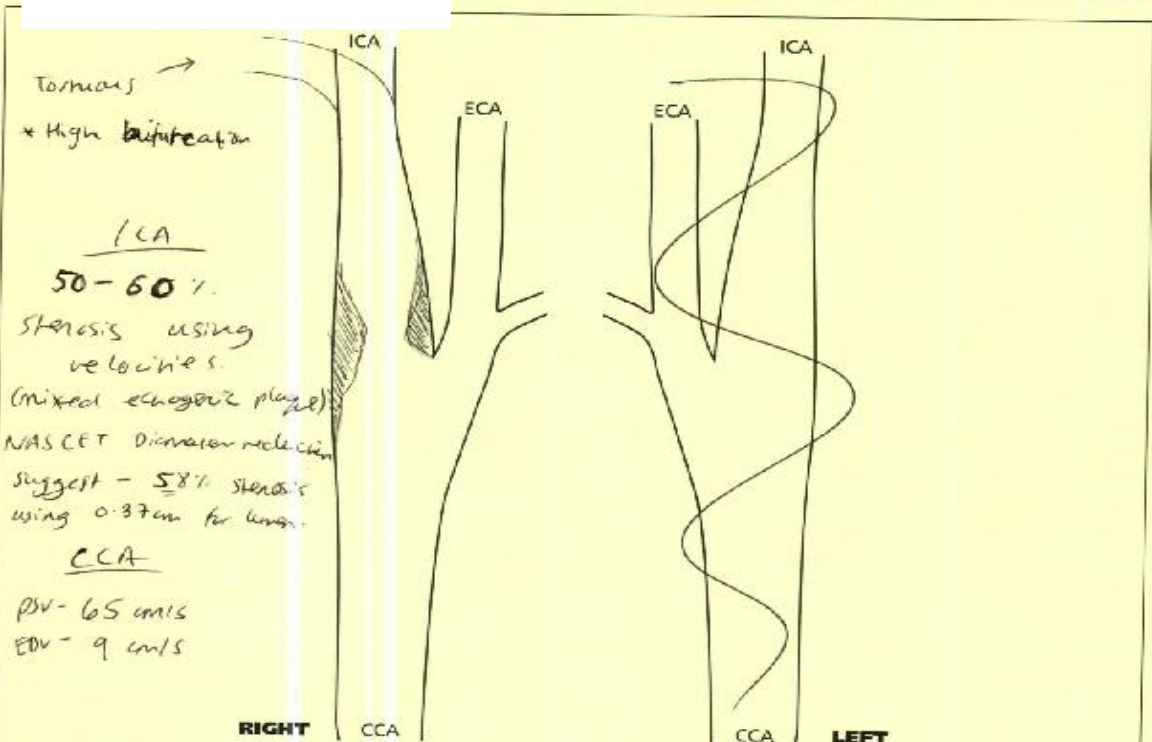
CONSULTANT: Mr Ray

DEPT: VACS

CLINICAL HISTORY: Referred repeat scan

HOSPITAL: GH

SUMMARY	%STENOSIS	ICA PSV cm/s	ICA EDV cm/s	VERTEBRAL FLOW
RIGHT	50-60	152	39	Ant
LEFT				



COMMENTS:

SIGNED: *[Signature]*

CLINICAL VASCULAR SCIENTIST

PRINT NAME: S. Fern

DATE: 5/4/22

IMAGE QUALITY:

GOOD ☒ POOR

Walsley/51711 GKH

VASCULAR STUDIES UNIT

Level 1
Glenfield Hospital
Tel: 0116 258 5440



University Hospitals
of Leicester
NHS Trust

CAROTID DUPLEX SCAN REPORT

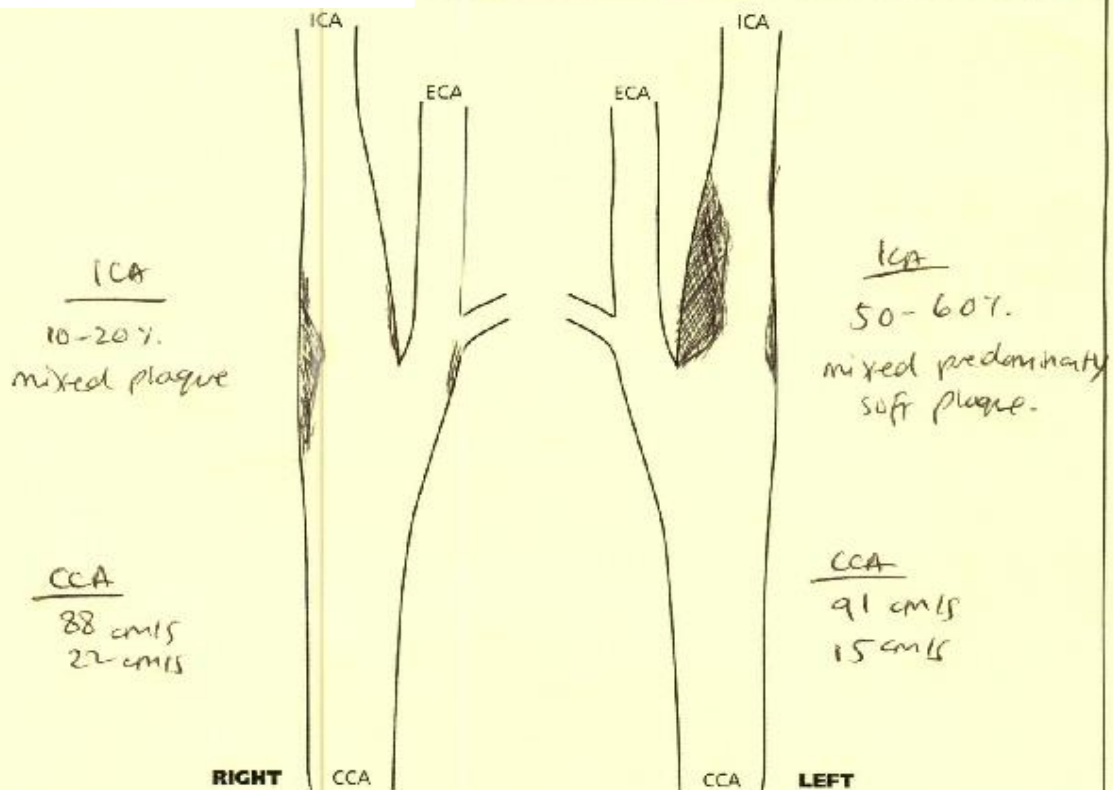
CONSULTANT: DR EVESON

DEPT: TIA clinic

CLINICAL HISTORY: @ sideclom
weakness

HOSPITAL: LPI

SUMMARY	%STENOSIS	ICA PSV cm/s	ICA EDV cm/s	VERTEBRAL FLOW
RIGHT	10-20	60	25	PLP
LEFT	50-60	200	85	AWD



COMMENTS:

SIGNED: *[Signature]*

CLINICAL VASCULAR SCIENTIST

PRINT NAME: S. Forster

DATE: 15/11/21

IMAGE QUALITY:

GOOD ☒ POOR

06/10/21 11:14:48

CAROTID DUPLEX SCAN REPORT

CONSULTANT: Dr Macmillan

DEPT: TIA Clinic

CLINICAL HISTORY: Intermittent loss of vision associated with right handclashes

HOSPITAL: GLH

SUMMARY	%STENOSIS	ICA PSV cm/s	ICA EDV cm/s	VERTEBRAL FLOW
RIGHT	0	64	19	RWD
LEFT	0	72	25	RWD

CCA
86 cm/s
17 cm/s

RIGHT

ICA

ECA

ECA

ICA

Clear

CCA
85 cm/s
23 cm/s

CCA

LEFT

COMMENTS:

SIGNED:

[Signature]

CLINICAL VASCULAR SCIENTIST

PRINT NAME:

S-feran

DATE: 6/4/22

IMAGE QUALITY:

GOOD ☐ ☒ POOR

19/04/2022 11:14:03

VASCULAR STUDIES UNIT

Level 1
Glenfield Hospital
Tel: 0116 258 5440

NHS

University Hospitals
of Leicester
NHS Trust

CAROTID DUPLEX SCAN REPORT

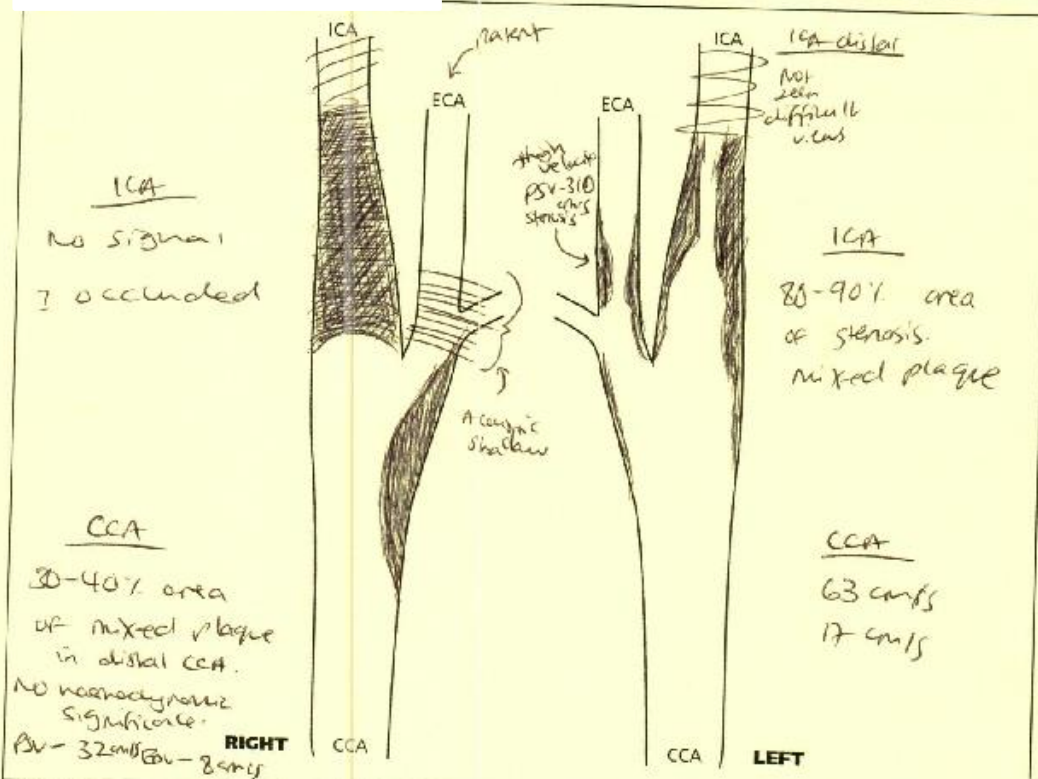
CONSULTANT: DR EVESON

DEPT: BTIA

CLINICAL HISTORY: ? (C) carotid disease

HOSPITAL: 47

SUMMARY	%STENOSIS	ICA PSV cm/s	ICA EDV cm/s	VERTEBRAL FLOW
RIGHT	0 cc occluded			FWD
LEFT	80-90	450	190	FWD



COMMENTS:

SIGNED: *[Signature]*

CLINICAL VASCULAR SCIENTIST

PRINT NAME: S. Fear

DATE: 15/11/21

IMAGE QUALITY:

GOOD ☒ POOR ☐

Waller 17114824

VASCULAR STUDIES UNIT

Level 1
Glenfield Hospital
Tel: 0116 258 5440



University Hospitals
of Leicester
NHS Trust

CAROTID DUPLEX SCAN REPORT

CONSULTANT: Dr Manning

DEPT: ~~Neurology~~ TIA Clinic

CLINICAL HISTORY: facial droop,
slurred speech, headache.

HOSPITAL: YCI

SUMMARY	%STENOSIS	ICA PSV cm/s	ICA EDV cm/s	VERTEBRAL FLOW
R GHT	<10	109	35	FWO
LEFT	10-20	89	34	FWO

ICA
10-20% mixed
plaque

CCA
122 cm/s
38 cm/s

RIGHT

CCA

ICA
10-20%
mixed predominantly
soft plaque

CCA
122 cm/s
38 cm/s

CCA

LEFT

COMMENTS:

SIGNED: [Signature]

CLINICAL VASCULAR SCIENTIST

PRINT NAME: Stefan

DATE: 25/1/22

IMAGE QUALITY:

GOOD ☐ ☒ POOR ☐

WALSLEY11-4401